

New frontiers in bariatric surgery laparoscopic adjustable silicone gastric banding (LASGB)

L. Angrisani *, M. Lorenzo, A. Puzziello, G. Romano, T. Santoro, A. Belfiore, G. Esposito, M. Fumo, O. Nicodemi, A. Petito, C. Falconi, B. Tesaro

Department of Surgery and Dietology, School of Medicine, 'Federico II' University, Naples, Italy

Abstract

LASGB is a minimally invasive procedure indicated for the treatment of morbid obesity. Since January 1996, six patients have successfully undergone the laparoscopic procedure. Preoperative BMI was 42 ± 3.1 ; range 39–46. Mean operative time was 260 ± 110 , range was 160–360. Mean hospital stay was 3 ± 1 days. © 1997 Elsevier Science Ireland Ltd.

1. Introduction

The role of surgery in the treatment of morbid obesity has been controversial. Recently the NIH Consensus Development Conference on gastrointestinal surgery for severe obesity has considered as potential candidates those with a body mass index (BMI) > 40, or BMI between 35 and 40 with high risk comorbid conditions [1]. Bariatric surgery is based on two fundamental concepts: malabsorption and gastric restriction. The most popular gastric restrictive procedure is the Mason vertical banded gastroplasty [2]. Kuzmak in 1986 introduced the silicone inflatable gastric banding [3]. Belachew and Cadriere, independently, showed the feasibility of the laparoscopic approach using the gastric banding [4,5]. This study reports the initial experience with LASGB performed in University of Naples opening the way in southern Italy to minimally invasive surgery for morbid obesity.

2. Patients and methods

From January 1996 to May, 27 patients with BMI > 35 were referred to the minimally invasive bariatric surgery outpatient clinic of 'Federico II' University in

Naples. The NIH criteria were required for patients to enter the protocol of preoperative investigations. Contraindication to LASGB are reported in Table 1. Clinical and laboratory preoperative investigations are summarized in Table 2. The operation is performed under general anesthesia with patients in the lithotomy and anti-Trendelenburg (30–45°) position. The arrangement of the surgical team and video-instrumentations, and trocars sites are reported respectively in Fig. 1 and Fig. 2. Closed CO₂ (12–14 mmHg) pneumoperitoneum is generally performed. The first step is measurement of the proximal gastric pouch using the INAMED calibrating tube balloon inflated to 20 ml. The surgical access through the hepatogastric ligament

Table 1
LASGB: contraindications

Gastrointestinal pathologies
Peptic disease
inflammatory diseases (i.e. Crohn)
Portal hypertension
Congenital diseases (i.e. Atresias, Stenosis)
Hyatal hernia (> 5–6 cm)
Previous Surgery on upper abdomen
Psychiatric disorders
Infections
Age < 16 years

* Corresponding author. Piazza Vittoria, 7, I-80121 Napoli, Italy

Table 2
Protocol of preoperative investigations for candidates to LASGB

Blood tests
routine
Epatitis markers
Thyroid hormones
Serum cortisol and gastrin
Clinical consultation of
Cardiology
Psychiatry
Endocrinology
Dietology
Pneumology
Anesthesiology
Orthopedy
Gastroenterology
Radiological examination of
Chest Head
Sella turcica
Gastrointestinal tract
Sonography of
Heart
Thyroid
Liver and biliary tract
Pancreas
Pelvic organs
Others
ECG
Spirometry
Endoscopy (helicobacter pilory)
Doppler lower limbs

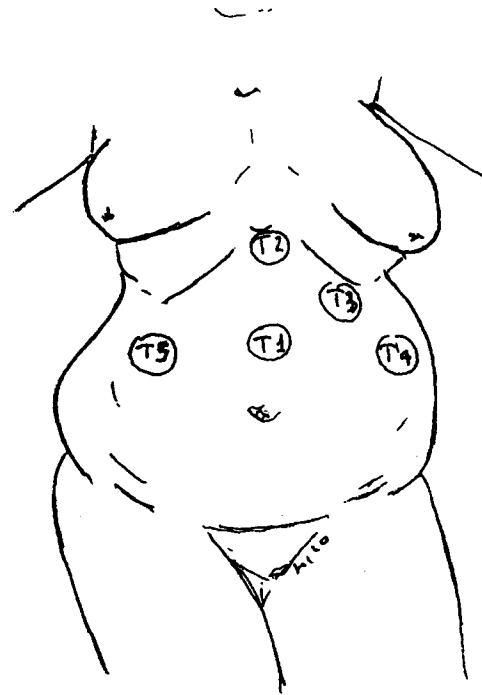


Fig. 2. LASB. Trocar sites. T1 = video camera; T2 = operator; T3 = operator (lap-band insertion); T4 = stomach retractor and T5 = liver retractor.

is obtained opening the avascular space between the Latarjet nerve and the lesser gastric curvature 3 cm below the cardias. The phrenogastric ligament is opened on the greater curve. A retrogastric tunnel is created by blunt dissection from the lesser to greater

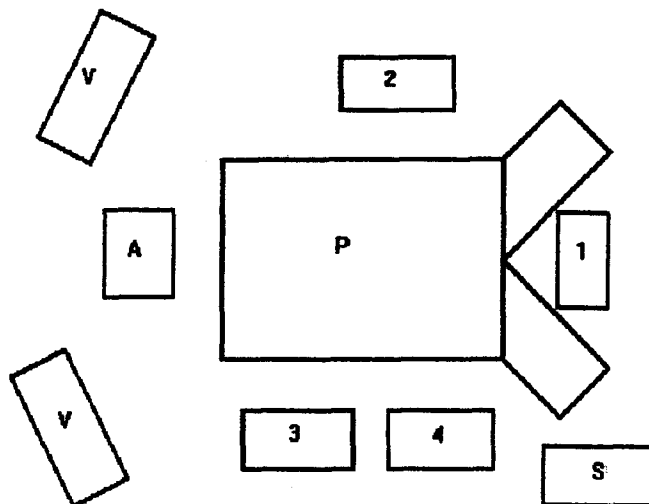


Fig. 1. LASGB. Arrangement of the surgical team and video instruments. P = patient in lithotomic position; 1 = surgeon; 2 = camera-man; 3 = assistant; 4 = instrument nurse; V = video and A = anesthetist.

curve. The band (INAMED Srl) is introduced into the peritoneum through a 33 mm port (Ethicon-Endosurgery) which replaces the left subcostal trocar. Routine gastro-stenometric control is performed before and after band closure. Three or four gastric seromuscular stitches from the proximal to the distal compartment prevent the band dislocation. The injection reservoir is connected to the inflatable silicone tube outside the abdomen and the entire system is fixed by nonabsorbable suture.

3. Results

Six female patients underwent an uneventful videolaparoscopic procedure (Mean age 38.6 ± 9.9 ; range 27-50. Mean BMI 42 ± 3.1 ; range 39-46). In one case associated laparoscopic cholecystectomy was performed. Mean operative time was 260 ± 110 min, range 160-360. Postoperative complications observed were an erosive gastritis of the proximal pouch ($n = 1$) and lung atelectasia ($n = 1$), both resolved conservatively. Mean hospital stay was 3 ± 1 days with full rehabilitation at discharge. Results in terms of weight loss expressed by BMI preoperatively and at follow-up per single patient are reported in Fig. 3.

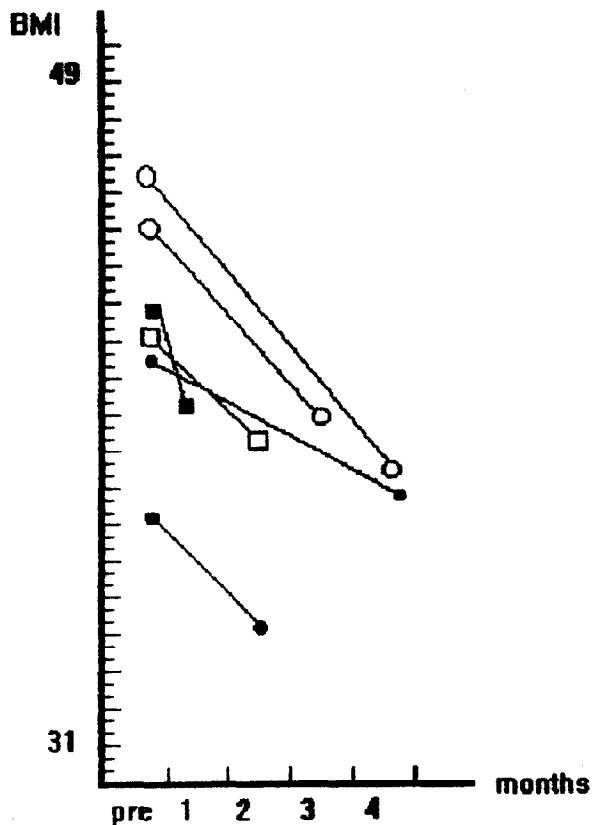


Fig. 3. LASGB. Weight loss of six patients.

4. Discussion

LASGB is an attractive procedure. The rationale of this operation is the dramatic reduction of the gastric volume to reduce food and caloric intake. This is obtained by a technique which is minimally invasive for the stomach and the abdominal wall. Since the proximal pouch is very small, the system is very powerful in controlling the diameter of the new pylorus, but it is also completely reversible. The results of gastric banding in terms of weight loss have been already proved by

prospective randomized trials comparing this technique with Mason procedures. The percentage of weight loss in the relative period of time, in fact, has been similar for the two groups of patients operated with different laparotomy techniques [6]. The laparoscopic approach for adjustable silicone gastric banding has been recently introduced in clinical practice in a few centers. The techniques which are presently available need further refinements and meticulous standardization. Early rehabilitation is an attractive goal for bariatric surgery which can be obtained through minimally invasive techniques and laparoscopy. Experience in advanced laparoscopy and laparoscopic general surgical procedure in obese patients is a basic requirement in performing LASGB [7]. Results of weight loss at long term follow-up of LASGB are awaited. With growing experience, LASGB could be considered a 'one day surgery' procedure in the near future.

References

- [1] NIH conference. Gastrointestinal surgery for severe obesity. Consensus development conference panel. *Ann Int Med* 1991;115(12):956–961.
- [2] Mason EE. Vertical banded gastroplasty for obesity. *Arch Surg* 1982;117:701–706.
- [3] Kuzmak LI. Silicone gastric banding. *Nat Bariatric Surg Registry Newsletter* 1986;1:12–17.
- [4] Belachew M, LLeGrand MJ, Defechereux TH, Burtheret MP, Jacquet N. Laparoscopic adjustable silicone gastric banding in the treatment of morbid obesity. A preliminary report. *Surg Endosc* 1994;8:1354–1356.
- [5] Cadiere GB, Bruyns J, Himpens J. Laparoscopic gastroplasty for morbid obesity. *Br J surg* 1994;81:1524–1527.
- [6] Belachew M, Jacquet P, Lardinois F, Karler C. Vertical banded gastroplasty vs. adjustable silicone gastric banding in the treatment of morbid obesity: a preliminary report. *Obesity Surg* 1993;3:275–278.
- [7] Angrisani L, Lorenzo M, De Palma G, Sivero L, Catanzano C, Tesaro B, Persico G. Laparoscopic cholecystectomy in obese patients compared with nonobese patients. *Surg Laparosc endosc* 1995;5(3):197–201.